Endoscopic Stapling System for Trans Oral Treatment of GERD — Three Years Follow Up

Aviel Roy-Shapira[1] and Amol Bapaye[2]

Department of Surgery A, Soroka Univesity Hospital, Beer Sheva, Israel (1) and Deenanath Mangeshkar Hospital and Research Center, Pune, India (2).

Introduction and Methods

This is a report of a three year follow up of 11 out of 13 subjects with moderate or severe GERD treated with a new totally endoscopic method,: The Medigus SRS Endoscopic stapling system. The system allows the operator to perform a true trans oral fundoplication.

Subjects were treated between May and October 2007, in the framework of a pilot study., and were contacted by phone during the first week of October 2010. The fol-

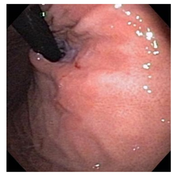

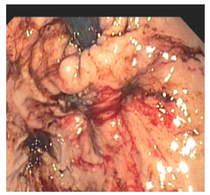

Stomach View

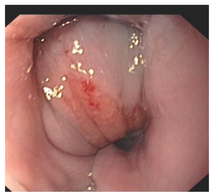

Esophagus View

Results:

11 of the 13 treated subjects could be reached by phone.

GERD-HRQL scores were <10 in 10 subjects

All but one improved score by > 50%. The one exception dropped from 29 to 15.

All subjects would repeat the procedure again.

3 subjects resumed PPI intake (compared to 2 at the 2 year follow up) 3 subjects continue to use PPI at a reduced dose, and one subject uses PPI only after a large meal. It should be noted, however, that before the procedure, these subjects were symptomatic while on PPI treatment. While now they are not. Four subjects are completely off PPI.

No subject reported dysphagia.



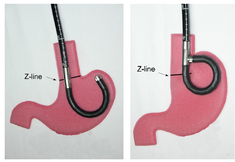

Discussion

After 3 years, the procedure remains effective in improving the quality of life of subjects with moderate to severe GERD. GERD-HRQL scores were reduced by 50% or more in about 80% of subject (counting the 2 missed subjects as failures) This is close to the reported long term result of surgical fundoplication(1)

In addition, PPI use was eliminated or reduced in 73% of subjects. In this respect, there was some change over time. There was one more subject who resumed PPI use at the 3 year mark than after 2 years. This phenomenon is also observed after surgical fundoplication.

Abstract

Introduction: Between May and October 2007, an IRB approved, pilot study of a new endoscopic stapling device for the treatment of GERD was conducted on 13 subjects in Pune, India. Subjects with history of PPI use > 2y for GERD and no co-morbidity were included. The device is a modified gastroscope, which includes a surgical stapler, that fires a staggered quintuplet of standard titanium B shaped 4.8mm staples, and an ultrasonic range finder. All procedures were done under general anesthesia by a single operator. Either 2 or 3 staple quintuplets were used to staple the fundus to the esophagus,creating a 90-180 degree anterior fundoplication over the distal 2-3cm of the esophagus. This is a report of the results of a three year follow up on this group of subjects

Methods: The original Informed consent specified that the subjects may be contacted annually for 5 years following the study. Accordingly subjects were contacted for a telephone interview during the first week of October 2010. The following data were collected: Velanovich GERD-HRQL scores, PPI use, symptoms, satisfaction with the procedure, and wllingness to repeat the procedure again.

Results: 11 of the 13 subjects could be reached by phone. GERD-HRQL scores were less than 9 or less in 10 subjects and 15 in one subject, The latter subject improved his score from 29 to 15, in all others score improved by more than 50%. All subjects would have agreed to do the procedure again. Mean satisfaction score was 7.7 (6-10) on a scale of 1-10. There was no dysphagia. Three subjects resumed PPI intake, (compared to 2 at the 2y follow up) 3 subjects require PPI at a reduced dose 1 subjects takes PPI only after a large meal and 4 subjects remained completely off PPI

Conclusions

In this small series, the long term efficacy of trans oral partial fundoplication using the Medigus SRS Endoscopic Stapling System for the treatment of moderate to severe GERD was safe and effective. Its success in improving quality of life approaches some reported results of laparoscopic fundoplication

Reference:

Gee DW et al: Measuring the effectiveness of laparoscopic antiferflux surgery—long term results: Arch Surg. 2008;143(5):482-487

Disclosures

1. Medical director of Medigus Ltd, and holds equity in the company